



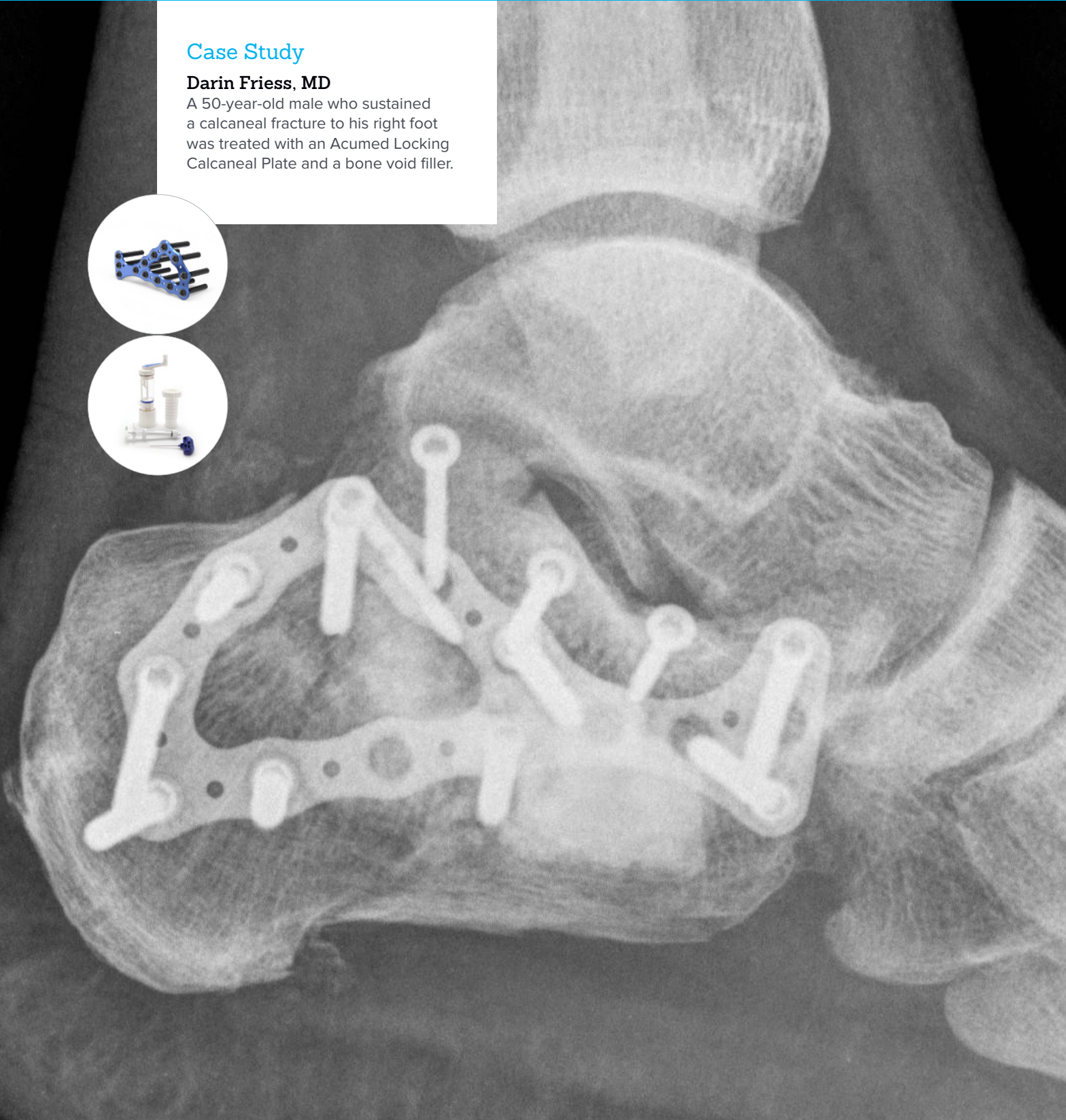Locking Calcaneal Plate and Callos® Bone Void Filler

## Right Calcaneus Fracture Treatment

### Case Study

#### Darin Friess, MD

A 50-year-old male who sustained a calcaneal fracture to his right foot was treated with an Acumed Locking Calcaneal Plate and a bone void filler.

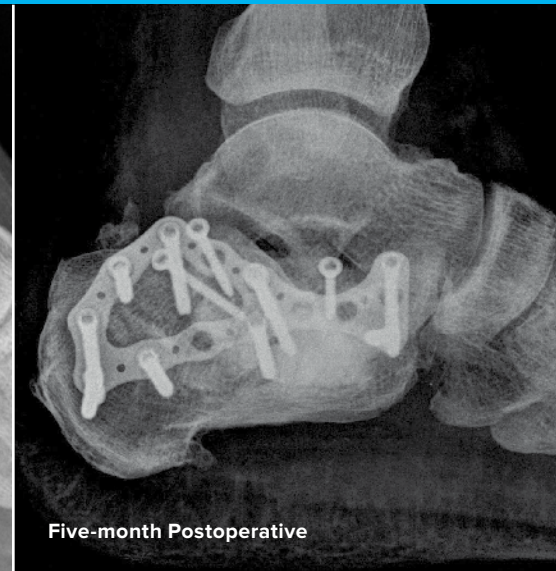
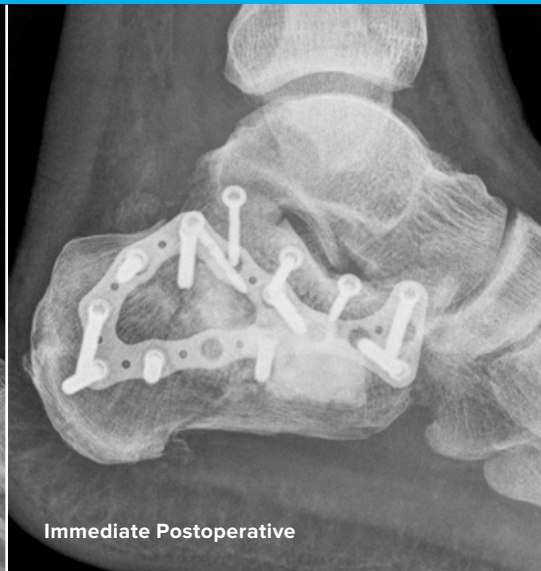
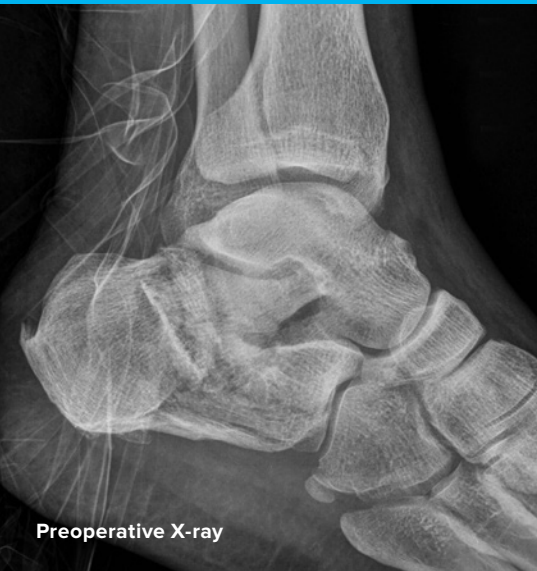
Acumed® is a global leader of innovative orthopaedic and medical solutions.



We are dedicated to developing products, service methods, and approaches that improve patient care.

## Case Study | Darin Friess, MD



## Right Calcaneus Fracture Treatment

### Patient History

A 50-year-old obese male (BMI 36) was involved in a motor vehicle collision. He sustained multiple injuries, including an unstable fracture of the thoracic spine, pelvic ring disruption, left acetabulum fracture, and right calcaneus fracture. After stabilization of his spine, pelvis, and acetabulum fractures, we discussed treatment options for his right calcaneus fracture. The fracture angulation in varus, displacement of Bohler's angle, and articular surface comminution were predictive of a poor outcome if treated nonsurgically. Additionally, since the left-sided acetabulum fracture would require prolonged non-weight-bearing, rigid fixation of the right calcaneus fracture would allow earlier mobilization on the right leg. Thus, the patient was taken to the operating room for open reduction and internal fixation (ORIF) of the right calcaneus fracture.

## Treatment

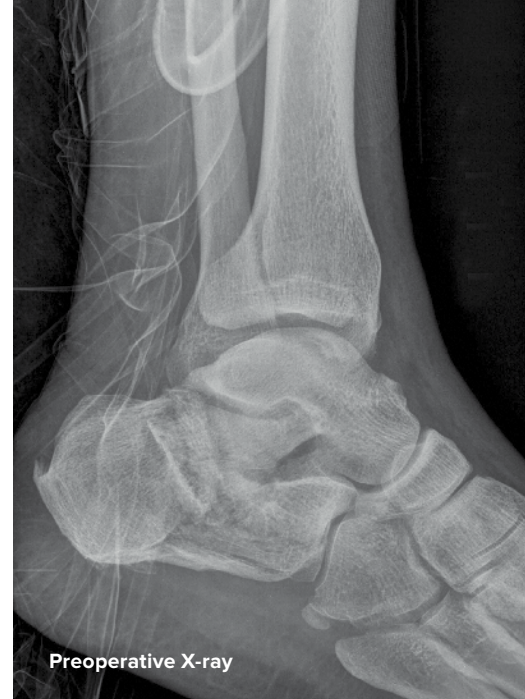Surgical ORIF of the right calcaneus fracture was performed through a standard lateral approach to the heel. The articular surface was reduced and stabilized using free lag screws. An Acumed precontoured low-profile calcaneal plate was placed laterally with a combination of lag screws and locking screws. Finally, an approximately 5 cc-size cancellous bone void was filled with Callos® Inject Calcium Phosphate Cement. Despite the patient's obesity and contralateral leg injuries, the fracture was stabilized with a locking calcaneal plate and Callos was used to fill the bone void, providing a stable platform for the patient to participate in standard initial-stage mobilization on the right leg.

## Postoperative Care

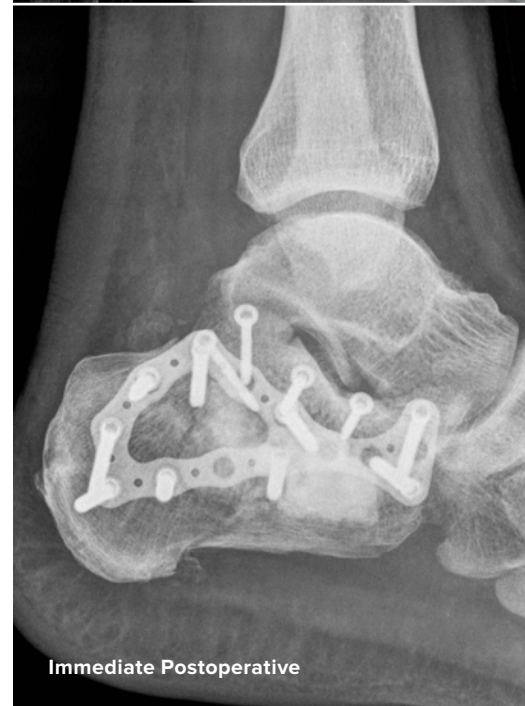Intra-operative fluoroscopy views demonstrated the reduction of the calcaneus fracture after plate and screw fixation and a large central cancellous bone void filled with Callos. The patient was allowed to transfer from bed to chair using his right foot for mobilization purposes. Radiographs at the five-month postoperative mark demonstrated no collapse of the fracture and excellent signs of initial radiographic healing. The patient has no pain in his foot and is very happy with the result.

## Discussion

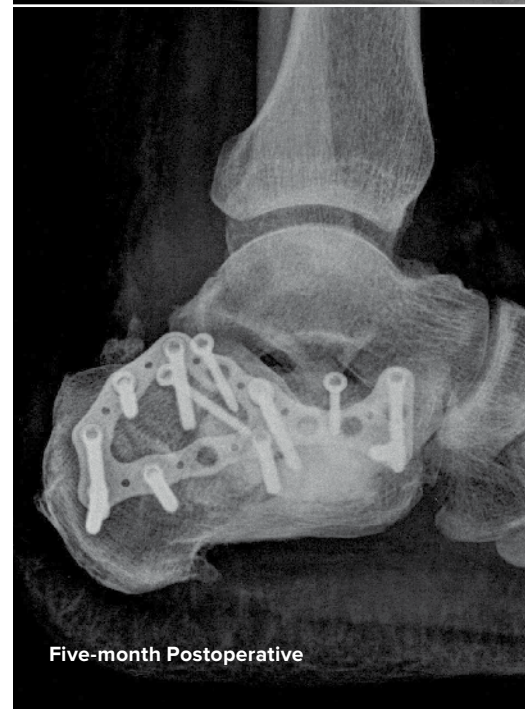Surgical treatment of the calcaneus fracture restored normal anatomical alignment and articular reconstruction to the hindfoot and led to an excellent outcome for this patient. Callos provides an immediately stable platform to buttress the articular reconstruction, which prevents collapse during the period of early fracture healing. The Callos will remodel over time and avoids ethical or infectious issues associated with cancellous bone graft. The precontoured Locking Calcaneal Plate provides an opportunity to place both nonlocking and locking screws in a low-profile plate to maintain the surgical alignment of the calcaneus.



Preoperative X-ray



Immediate Postoperative



Five-month Postoperative



## **BIO70-10-A**

Effective: 2018/03

© 2018 Acumed® LLC

Acumed® Headquarters  
5885 NE Cornelius Pass Road  
Hillsboro, OR 97124  
Office: 888.627.9957  
Fax: 503.520.9618  
[www.acumed.net](http://www.acumed.net)

These materials contain information about products that may or may not be available in any particular country or may be available under different trademarks in different countries. The products may be approved or cleared by governmental regulatory organizations for sale or use with different indications or restrictions in different countries. Products may not be approved for use in all countries. Nothing contained on these materials should be construed as a promotion or solicitation for any product or for the use of any product in a particular way which is not authorized under the laws and regulations of the country where the reader is located. Specific questions physicians may have about the availability and use of the products described on these materials should be directed to their particular authorized Acumed distributor. Specific questions patients may have about the use of the products described in these materials or the appropriateness for their own conditions should be directed to their own physician.

Acumed® is a registered trademark of  
Acumed LLC

Callos® is a registered trademark of and is  
manufactured by Skeletal Kinetics LLC

