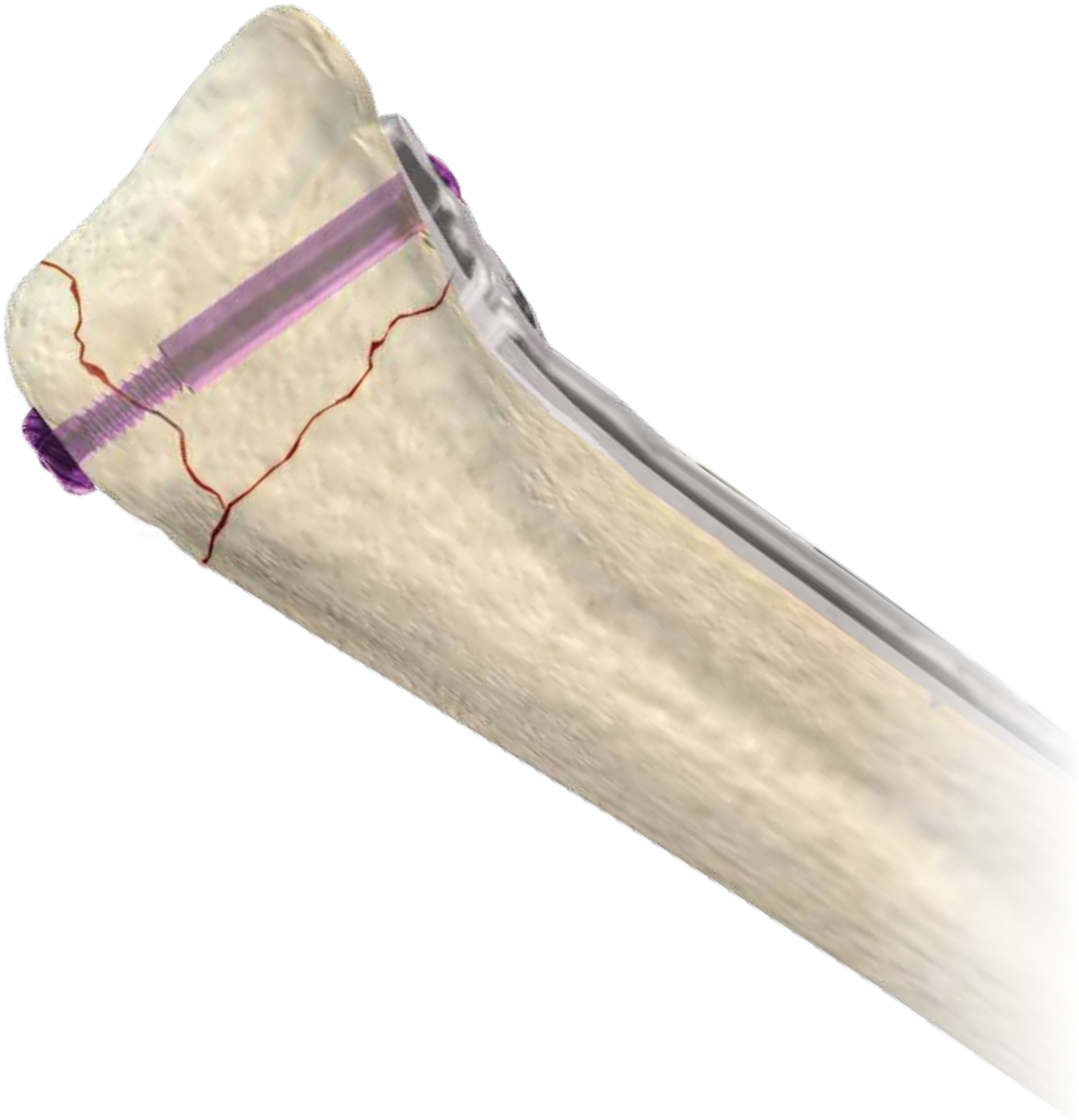


Case Study: Fixation of Distal Radius Fracture

Treated with the Acu-Loc® VDR Plate and Frag-Loc® Compression Screw



Case Series: Acu-Loc® VDR Plate and Frag-Loc® Compression Screw

INDICATION: Frykman Type IV Distal Radius Fracture

PRODUCTS: Acumed® Acu-Loc® VDR Plate and Frag-Loc® Compression Screw

SURGEON: Edward Reece, M.D., M.S.

PATIENT HISTORY

This is an 85 year-old, right hand dominant female who sustained a ground level fall on an outstretched hand. She sustained a Frykman IV, Melone class I closed distal radius fracture that had three intra-articular components. The ulnar column component was split transversely. The Frag-Loc® Compression Screw was ideal for this type of fracture that is classified as unstable.

TREATMENT

Treatment included open reduction internal fixation of her comminuted distal radius fracture. The Frag-Loc® Compression Screw was used to compress and stabilize an unstable comminuted ulnar column fragment.

POSTOPERATIVE RESULTS

The patient was admitted post-operatively to a skilled nursing facility that did not offer hand therapy. Despite this, her wrist supination and pronation at six weeks was 50°. Wrist Flexion was 45° and wrist extension was 30°. She complained of no wrist pain. There was no tenderness to palpation on physical examination.

DISCUSSION

With the exception of using a dorsal plating system, there are no good products on the market for treating complex distal radius fractures with intra-articular transverse components effectively, especially the dorsal lip fragments. Most distal radius volar plating systems rely on screw fixation with the intention to bring dorsal cortical fragments together.

The reliability of compression from a dorsal to volar fragment using traditional volar plate and screw fixation is questionable. The Frag-Loc® Compression Screw gives the option to the surgeon for steadfast dorsal compression and a surface area under the screw head that can encompass several fragments. Moreover, only a small incision is required dorsally to implement this device.

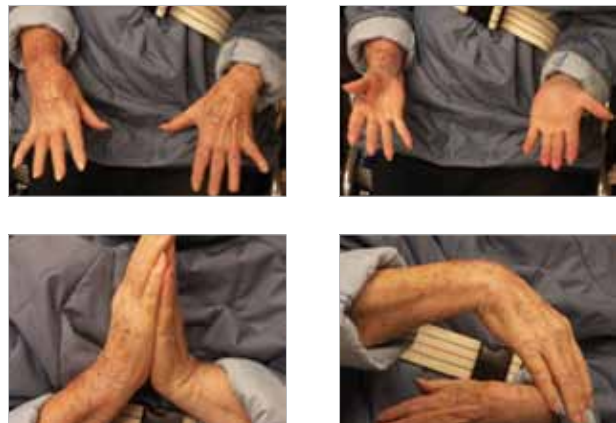

FIGURE 1: Preoperative X-ray

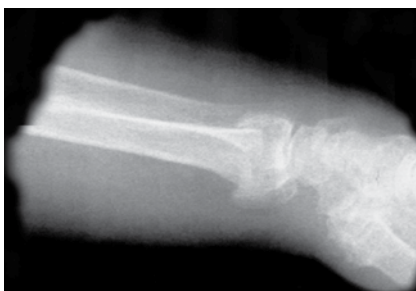

FIGURE 2: Postoperative X-ray

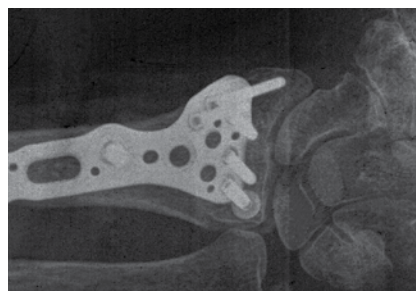


FIGURE 3: 6 Week Post-Op X-ray

